

An Unusual Case of Traumatic Optic Neuropathy

*Dr. S. Padmavathy, Medical Consultant, Tirunelveli and Dr. Kaustubh B. Harshey,
Aravind Eye Hospital,*

Abstract

Traumatic optic neuropathy is a frequent cause for visual loss in young patients sustaining head injuries. Bilateral traumatic optic neuropathy is rare. We present a case of bilateral traumatic optic neuropathy with bilateral optic canal fractures following a minor road traffic accident with an incidental associated left internal carotid artery dissection. The patient eventually suffered complete blindness but with surprisingly asymptomatic internal carotid artery dissection.

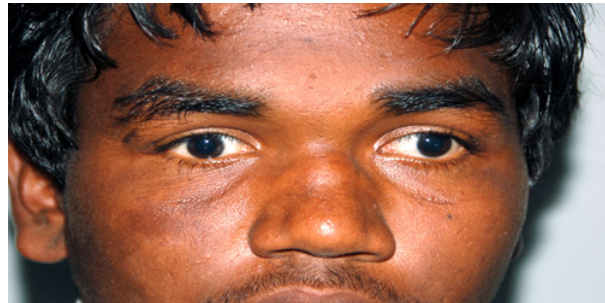Introduction

Traumatic optic neuropathy is a common cause of blindness following optic nerve injury due to cranio-orbital trauma. It usually affects young individuals especially males who are more prone to road traffic accidents. The clinical spectrum can range from subtle visual field defects to overt blindness. In many instances, traumatic optic neuropathy is associated with injuries on the face, brain, spine and other organs depending on the severity of the initial injury. Here we present the case of a young male with bilateral traumatic optic neuropathy, bilateral optic canal fracture and associated left internal carotid artery dissection.

Case Summary

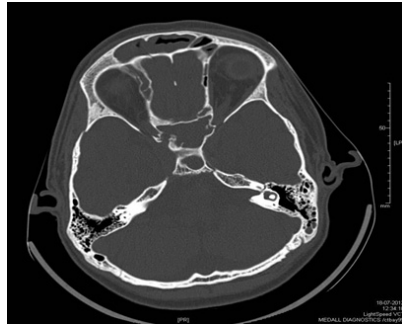
A 17 year old man presented to us with complaints of sudden loss of vision in both eyes (BE) since 20 days following a fall from the tractor. He had a loss of consciousness for 10 minutes following the fall. There was an associated history of one episode of vomiting post trauma, bleeding from nose, severe throbbing headache and a clear nasal discharge. Patient was admitted to a general hospital for 12 days and received intravenous methyl prednisolone injections for 3 days without improvement in

vision. The report of Computed Tomography (CT) of the brain was suggestive of acute subarachnoid hemorrhage with pneumocephalus, fracture of bilateral maxillary sinus walls, right sphenoid wing and right temporal bone with hemosinus. There were no images available with the patient. On examination, systemic parameters were within normal limits. Ocular examination showed a visual acuity of No perception of light (PL) in both eyes. Anterior segment examination was normal apart from bilateral 4.5mm fixed dilated pupils not reacting to light. Fundus examination at this point was normal.

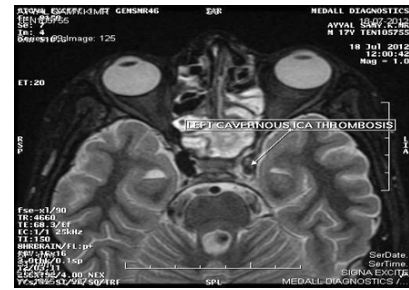
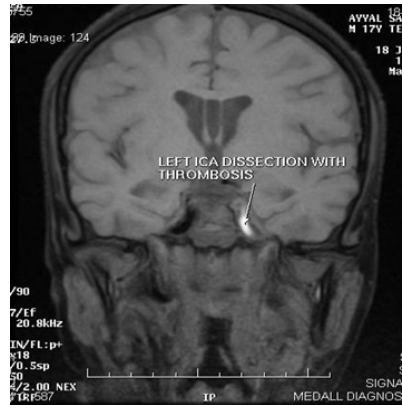
Central nervous system was normal apart from the bilateral visual loss. Since bilateral visual loss was not being supported by the imaging evidence and patient had a history of subarachnoid hemorrhage, we went ahead with a higher modality of neuroimaging in the form of magnetic resonance imaging (MRI) with magnetic resonance angiography (MRA) along with a CT screening of the brain. CT revealed a bilateral optic canal fracture along with post traumatic edema of the optic nerve. MRI and MRA surprisingly showed a left internal carotid artery dissection (ICAD) in its cervical and intracavernous part.

Patient was urgently referred to a tertiary neurosurgical center for management of the ICAD and was given oral steroids in tapering doses. At



Bilateral Optic Canal Fracture: CT



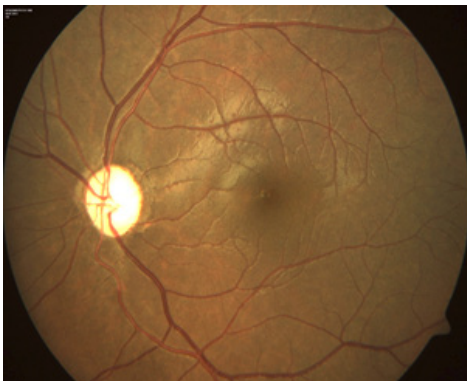
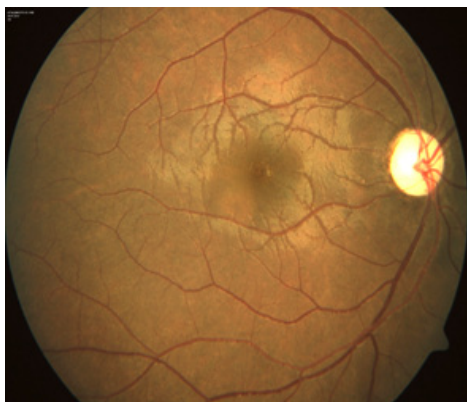
this last visit his visual acuity was status quo with bilateral fixed dilated pupils. Fundus examination showed bilateral primary optic atrophy. He had no headache and was not symptomatic for ICAD. Patient was given blindness certificate, protective glasses and referred to a rehabilitation center.

Discussion

Traumatic optic neuropathy (TON) occurs in 0.5-5% of closed head injuries[1] and 2.5% of maxillofacial or midfacial trauma.[2] Loss of consciousness is seen in 40-70% cases.[3] The

age group most frequently involved is from 20-40yrs. It is usually unilateral, but can be bilateral in 5-6% cases. [4] Deceleration injury to ipsilateral forehead or supraorbital ridge following a road traffic accident is the most common mechanism. TON can be direct or indirect. Indirect TON can be anterior, posterior or chiasmal. Clinical evaluation of TON includes assessment of visual acuity, pupils, detailed ocular examination, visual fields, colour vision, visual evoked potentials and assessment of associated trauma to other organ systems. High resolution CT is the imaging procedure of choice in suspected cases. MRI may be useful in select situations. [5] Often both imaging modalities are required. Treatment of TON is controversial. No randomized controlled trial has proved the efficacy of corticosteroids or optic nerve decompression. [6].

Treatment should be individualized. 57% patients improve spontaneously untreated. [6] Carotid artery dissection (CAD) is the separation of the carotid artery wall between the tunica intima and tunica media. It usually affects the population between the 3rd-5th decade with cases fatality of up to 31% in traumatic cases. [7] CAD can be spontaneous or traumatic. Traumatic cases are usually due to a rapid deceleration injury, whiplash injuries, neck strain or manipulation and penetrating trauma. Blood dissects within the carotid artery wall forming an intramural hematoma which compresses the true lumen leading to distal ischemia. Consequently, this hematoma may thrombose and



lead to embolization with distal infarction. CT angiography is the procedure of choice.[8] Exact management guidelines do not exist. Patient can be treated with antiplatelets and anticoagulants when not contraindicated. Surgical intervention maybe needed in certain cases. Our patient demonstrated a bilateral TON which is reported rarely in literature. Probably the mechanism of injury was responsible for the development of the associated ICAD. Asymptomatic ICAD is

only rarely reported in literature.[9], [10] ICAD may be associated with ocular complications[11] and even ischemic optic neuropathy[12] which however were absent in our patient. In conclusion, we would suggest that patients with head injuries and road traffic accidents presenting to the ophthalmologist should be examined and treated with a high index of suspicion for associated life threatening complications of trauma.

References:

1. Steinsapir KD, Goldberg RA. Traumatic optic neuropathy. *Surv Ophthalmol.* 1994 May-Jun;38(6):487-518.
2. al-Qurainy IA, Stassen LF, Dutton GN, Moos KF, el-Attar A. The characteristics of midfacial fractures and the association with ocular injury: a prospective study. *Br J Oral Maxillofac Surg.* 1991 Oct;29(5):291-301.
3. Edmund J, Godtfredsen E. Unilateral optic atrophy following head injury. *Acta Ophthalmol (Copenh).* 1963;41:693-7.
4. Mahapatra A K. Bilateral optic nerve injury. *Neurol India* 1999;47:92
5. Seiff SR. High dose corticosteroids for treatment of vision loss due to indirect injury to the optic nerve. *Ophthalmic Surg.* 1990 Jun;21(6):389-95.
6. Levin LA, Beck RW, Joseph MP, Seiff S, Kraker R. The treatment of traumatic optic neuropathy: the International Optic Nerve Trauma Study. *Ophthalmology.* 1999 Jul;106(7):1268-77.
7. Kerwin AJ, Bynoe RP, Murray J, Hudson ER, Close TP, Gifford RR, Carson KW, Smith LP, Bell RM. Liberalized screening for blunt carotid and vertebral artery injuries is justified. *J Trauma.* 2001;51:308-14.
8. Caplan LR. Dissections of brain-supplying arteries. *Nat Clin Pract Neurol.* Jan 2008;4(1):34-42.
9. Hughes KM, Collier B, Greene KA, Kurek S. Traumatic carotid artery dissection: a significant incidental finding. *Am Surg.* 2000 Nov;66(11):1023-7.
10. Fuse T, Ichihashi T, Matuo N. Asymptomatic carotid artery dissection caused by blunt trauma. *Neurol Med Chir (Tokyo).* 2008 Jan;48(1):22-5.
11. Biousse V, Touboul PJ, D'Anglejan-Chatillon J, Lévy C, Schaison M, Bousser MG. Ophthalmologic manifestations of internal carotid artery dissection. *Am J Ophthalmol.* 1998 Oct;126(4):565-77.
12. Valérie Biousse; Monique Schaison, Pierre-Jean Touboul, Jacques D'Anglejan-Chatillon, Marie-Germaine Bousser. Ischemic Optic Neuropathy Associated With Internal Carotid Artery Dissection. *Arch Neurol.* 1998;55(5):715-719.3)